


Chronic Spontaneous Urticaria Patient Developing Idiopathic Anaphylaxis and Responding to Omalizumab Treatment: Case Report

Oner OZDEMİR¹ , Ummugulsum DIKICI¹ , Busra Sultan KIBAR² 

¹ Division of Allergy and Immunology, Department of Pediatrics, Sakarya University Faculty of Medicine, Research and Training Hospital of Sakarya University, Sakarya, Türkiye

² Department of Pediatrics, Sakarya University Faculty of Medicine, Research and Training Hospital of Sakarya University, Sakarya, Türkiye

Corresponding Author: Oner Ozdemir ✉ ozdemir_oner@hotmail.com

ABSTRACT

Anaphylaxis in which no triggering cause can be demonstrated is called idiopathic anaphylaxis (IA). Idiopathic anaphylaxis is a life-threatening disease with symptoms similar to other forms of anaphylaxis. Although rare, it is clinically important due to the risk of morbidity and mortality. There is currently no standard long-term prophylaxis regimen for IA. The use of omalizumab was beneficial in some patients who did not respond to treatment.

We report a 16-year-old girl with chronic spontaneous urticaria who was later diagnosed with IA and was successfully treated with omalizumab. Subcutaneous omalizumab treatment was started in our patient who did not respond to antihistamines and mast cell stabilizers. Omalizumab treatment was initially started at 150 mg/month and the dose was increased to 300 mg/month when the attack recurred.

Allergists should keep in mind that patients with chronic spontaneous urticaria might develop IA, which is responsive to omalizumab.

Keywords: Omalizumab, idiopathic anaphylaxis, urticaria, anti-Ig E

INTRODUCTION

Anaphylaxis usually occurs suddenly after exposure to a known or unknown allergen. Cases where the cause of the anaphylaxis could not be revealed despite detailed investigations and the presence of conditions such as systemic mastocytosis that may be associated with anaphylaxis has not been demonstrated are called “idiopathic anaphylaxis (IA)” (1,2). Idiopathic anaphylaxis has now been described in childhood and adulthood. There is an increase in cases all over the world. Although IA can be controlled with appropriate treatment regimens, it is potentially fatal. It causes anxiety in the patient and his family. It is included in the major health expenditures. The fact that it is a corticosteroid-responsive disease suggests that the disease may have an immunological pathogenesis. Treatment regimens used in prophylaxis management are effective. In the com-

pared case series of IA in the literature, a few deaths have been reported (3).

Signs and symptoms do not differ from anaphylaxis with a known cause. Although mild attacks may occur, IA attacks that threaten life or result in death may be observed (1,2). Antihistamines, corticosteroids, and montelukast are used in the treatment of IA. In patients unresponsive to antihistamine treatment, omalizumab treatment is also among the alternative treatment options due to its low potential for side effects.

Case series using omalizumab in IA cases have been published in the literature. In this report, we would like to present a case in which chronic spontaneous urticaria (CSU) and IA symptoms were controlled with omalizumab treatment.

CASE PRESENTATION

A 16-year-old girl has been suffering from urticaria attacks that lasted for 1 week, the etiology of which was unknown, for the last eight years. The frequency of urticaria attacks had diminished over the past couple of years. 12 months ago, swelling and itching began for the first time on her hand after dinner, and then she became dizzy and experienced shortness of breath. She applied to the emergency room within 15 minutes, adrenaline was administered, and the complaints regressed. Two days after the first anaphylaxis, similar symptoms developed again. They applied to the emergency room and adrenaline was administered once again. Cetirizine 10mg/day and pheniramine 2mg/kg/day were started. The patient was issued an adrenaline autoinjector report suitable for his age. The patient, who continued to have similar but milder symptoms, had 4 anaphylaxis attacks in 8 days, 2 days apart, and applied to our outpatient clinic of pediatric allergy.

When applying to our polyclinic, there was no reason detected for anaphylaxis that had been going on for 1 year. Hemogram and sedimentation values were normal. There was no eosinophilia in the hemogram (149/ μ l). Immunoglobulin (Ig) G, A, and M values were normal. Total IgE was 125 IU/mL. Specific IgE testing was negative for indoor and outdoor inhalant allergens. C1 inhibitor esterase, C3, and C4 levels were normal. Within one episode, serum tryptase (2.36 μ g/L) and urine histamine values were normal. Thyroglobulin antibody (55.80 IU/ml) and

anti-thyroid peroxidase antibodies (184.1 IU/ml) were positive. Thyroid-stimulating hormone (TSH) and thyroid hormone levels were found to be normal. Anti-nuclear antibody (ANA), rheumatoid factor (RF), and anti-gliadin IgA were negative. Evaluations for stool parasites, *Helicobacter pylori*, and hepatitis B virus were negative. Vitamin B12, ferritin, and folic acid values were found to be normal. Vitamin D level was found to be low (5.31 μ g/L).

As a result of consultation with endocrinology about the results of the thyroid gland, which was thought to be related to the etiology of CSU, it was said that nothing was needed at this stage except for follow-up. In addition, the relationship with any known triggering factor could not be established with these clinical and laboratory findings and the diagnosis of IA was made. Montelukast was added to the patient's cetirizine and pheniramine treatment. When there was no response to this combined treatment, it was decided to start monthly 150 mg subcutaneous omalizumab treatment with the thought that it would be good for controlling both the urticaria and IA. The patient had one more anaphylaxis after the seventh dose under omalizumab treatment. The dose of omalizumab was increased to 300 mg/month. During the next eight months of omalizumab treatment alone, she had no exacerbations. The patient's response to omalizumab treatment is shown in Figure 1, and the change in the urticaria activity score (UAS7), and the change in the urticaria control test (UCT) scoring in Figure 2. (Informed consent was obtained from the patient's family for this presentation.)

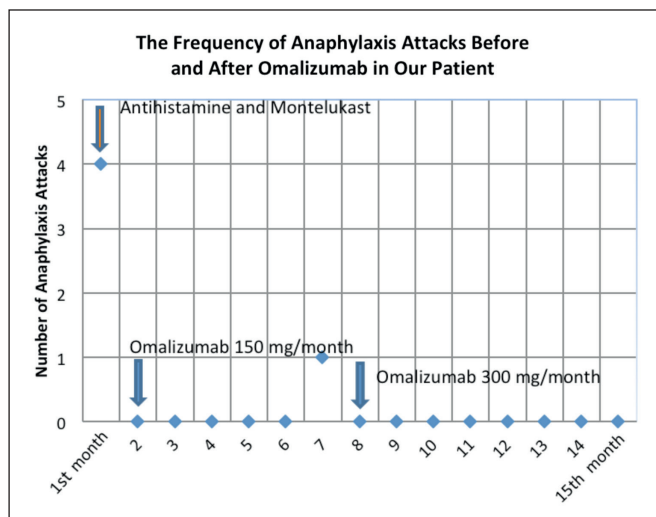


Figure 1. Number of anaphylaxis attacks in our patient.

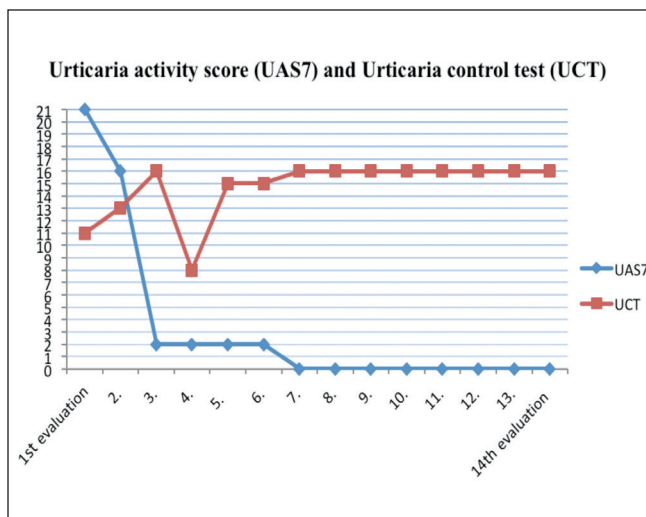


Figure 2. Change in urticaria activity score (UAS7) and urticaria control test (UCT) scoring in the follow-up of our patient

DISCUSSION

Consistent with the literature, anti-thyroglobulin and anti-thyroid peroxidase antibodies were found to be positive in our case during the laboratory investigation for the etiology of CSU. However, thyroid stimulating hormone (TSH) and thyroid hormone levels were normal. Autoimmune thyroid disease or the positivity of thyroid autoantibodies are the most frequently investigated disorders in cases with CSU. Studies have reported that the incidence of thyroid autoantibodies varies between 6.5% and 57% (4-6). In a study by Irinyi et al. evaluating 109 chronic urticaria cases, autoimmune disease was found in the history of 22%. The most common ones were autoimmune thyroiditis, vitiligo, and rheumatoid arthritis (5). In a large study including 12,778 cases in which autoimmune diseases and serological markers were investigated in a case of CSU, the most common accompanying clinical picture was again determined as thyroid diseases. Hypothyroidism was found in 9.8% of the cases and hyperthyroidism in 2.6% (7). In a study by Akarsu et al., 4.8% of 146 cases diagnosed as CSU were found to have an anti-thyroglobulin antibody and 9.6% anti-thyroid peroxidase antibody positivity (8).

Anaphylaxis is defined as a severe, life-threatening systemic hypersensitivity reaction (9). As in our patient, IA is defined when other causes are excluded and there is no specific trigger. Since its etiology is not known for certain, the treatment and care are difficult (1-3).

Studies on the course and treatment response of CSU in children are limited. In a prospective study in children, 92 children aged 4-15 years were considered in remission if symptoms did not recur for at least 12 months after disease onset, and remission rates after 1, 3, and 5 years were 18.5%, 54%, and 67%, respectively. No factor determining remission was found. There was no difference between the presence of autoimmunity and remission rates (10). In a prospective observational study of 6 months duration, the rate of patients who entered remission in 6 months with step therapy was found to be 39% (11). However, in a study comparing the relationship between chronic urticaria and laboratory tests, disease severity and duration were found to be associated with advanced age and positive thyroid antibodies (12). In a study by Şahiner et al., female gender older than 10 years of age was found to have a poor prognosis in terms of resistance to treatment in CSU (13). The course of the disease in our patient who was female, was

positive for thyroid antibodies, and developed IA could be thought to be somewhat severe. In our literature search, the course and rate of developing IA in CSU could not be found.

Treatment of attacks according to management guidelines should be planned. Prednisone, H1-antihistamines, and adrenaline are resources. Omalizumab is a monoclonal anti-IgE antibody. Anti-IgE has been recently started to be utilized in IA cases (14). It acts on IgE by binding to high-affinity receptors (FcεRI) on mast cells and basophils (15). Recently, positive results of anti-IgE (omalizumab) therapy have been reported in allergic rhinitis, especially asthma, and in complex and difficult-to-treat urticarial/anaphylactic cases (15). Jones et al. reported in 2008 that omalizumab treatment was effective in a 12-year-old male patient with episodes of uncontrolled asthma, allergic rhinitis, multiple food allergies, and anaphylaxis (14). Özdemir et al. have shown the effect of omalizumab in a 16-year-old girl who was diagnosed with steroid-dependent malignant IA (16). Pitt et al. reported that omalizumab was effective in a 15-year-old girl who was diagnosed with IA due to systemic mastocytosis (17).

Similar examples exist for adult patients. Recently, it has been demonstrated in case reports that omalizumab treatment prevents relapse in these resistant patients (14,18). In the IA case series of 335 patients aged between 5 and 83 years conducted by Ditto et al., it was reported that omalizumab treatment prevented relapse (2). Lee reported that they treated a 41-year-old male patient diagnosed with IA, who had six attacks in seven months, with 300 mg of omalizumab per month, and that he had no attacks in the 13 months after omalizumab prophylaxis, and that it could be an option to prevent anaphylactic events (19). Demirtürk et al. reported that attacks were controlled with omalizumab in a 46-year-old female patient with severe, uncontrolled allergic asthma and IA (20).

The literature on omalizumab as an effective reality is growing. Our patient had frequent episodes under CSU prophylaxis treatment. Monthly 300 mg omalizumab treatment was started. Our patient did not have any attacks during the eight-month follow-up with anti-IgE (Omalizumab) treatment. Similar to the mentioned literature, our patient has been also responsive to omalizumab therapy and has good control of the disease. Omalizumab did prevent both the attacks of IA and CSU.

In conclusion; although the cases reported in the literature are limited, anti-IgE therapy in IA has come to the fore in recent years. Omalizumab (anti-Ig E) therapy may be an effective treatment option in patients with IA who do not respond to antihistamines and mast cell stabilizers or who have attacks despite steroid therapy. Successful results have been reported in studies with omalizumab. It offers clinicians a safe treatment option with its low side-effect profile, and rapid and high efficacy, especially in cases with recurrent or treatment-resistant IA.

Conflict of Interest

No conflict of interest.

Funding

No Funding sources.

Authorship Contributions

Concept: **Oner Ozdemir, Ummugulsum Dikici**, Design: **Busra Sultan Kibar**, Data collection or processing: **Ummugulsum Dikici, Busra Sultan Kibar**, Analysis or Interpretation: **Oner Ozdemir, Ummugulsum Dikici**, Literature search: **Oner Ozdemir, Ummugulsum Dikici, Busra Sultan Kibar**, Writing: **Oner Ozdemir, Ummugulsum Dikici, Busra Sultan Kibar**, Approval: **Oner Ozdemir, Ummugulsum Dikici, Busra Sultan Kibar**.

REFERENCES

- Greenberger PA. Idiopathic anaphylaxis. *Immunol Allergy Clin North Am* 2007;27:273-93.
- Ditto AM, Harris KE, Krasnick J, Miller MA, Patterson R. Idiopathic anaphylaxis: A series of 335 cases. *Ann Allergy Asthma Immunol* 1996;77:285-91.
- Özdemir Ö. Idiopathic anaphylaxis: Diagnosis and treatment. *Medeniyet Medical Journal* 2018;33(4):326-35.
- Konstantinou GN, Asero R, Ferrer M, Knol EF, Maurer M, Raap U, et al. EAACI taskforce position paper: Evidence for autoimmune urticaria and proposal for defining diagnostic criteria. *Allergy* 2013;68:27-36.
- Irinyi B, Széles G, Gyimesi E, Tumpek J, Herédi E, Dimitrios G, et al. Clinical and laboratory examinations in the subgroups of chronic urticaria. *Int Arch Allergy Immunol* 2007;144:217-25.
- Sánchez-Borges M, Ansotegui IJ, Baiardini I, Bernstein J, Canonica GW, Ebisawa M, et al. The challenges of chronic urticaria part 1: Epidemiology, immunopathogenesis, comorbidities, quality of life, and management. *World Allergy Organ J* 2021;14(6):100533.
- Confino-Cohen R, Chodick G, Shalev V, Leshno M, Kimhi O, Goldberg A. Chronic urticaria and autoimmunity: Associations found in a large population study. *J Allergy Clin Immunol* 2012;129:1307-13.
- Akarsu S, İlknur T, Özbağcıvan Ö, Fetil E. Accompanying conditions in patients with chronic spontaneous urticaria and urticarial vasculitis: Results of a retrospective study. *Turkderm-Turk Arch Dermatol Venereol.* 2015;49(1):18-24.
- Simons FE. Anaphylaxis. *J Allergy Clin Immunol* 2010;125:161-81.
- Chansakulporn S, Pongpreuksa S, Sangacharoenkit P, Pacharn P, Visitsunthorn N, Vichyanond P, et al. The natural history of chronic urticaria in childhood: A prospective study. *J Am Acad Dermatol* 2014;71:663-8.
- Ye YM, Park JW, Kim SH, Ban GY, Kim JH, Shin YS, et al. Prognostic factors for chronic spontaneous urticaria: A 6-month prospective observational study. *Allergy Asthma Immunol Res* 2016;8:115-23.
- Toubi E, Kessel A, Avshovich N, Bamberger E, Sabo E, Nusem D, et al. Clinical and laboratory parameters in predicting chronic urticaria duration: A prospective study of 139 patients. *Allergy* 2004;59:869-73.
- Sahiner UM, Civelek E, Tuncer A, Yavuz ST, Karabulut E, Sackesen C, et al. Chronic urticaria: Etiology and natural course in children. *Int Arch Allergy Immunol* 2011;156(2):224-30.
- Jones JD, Marney SR Jr, Fahrenholz JM. Idiopathic anaphylaxis successfully treated with omalizumab. *Ann Allergy Asthma Immunol* 2008;101:550-51.
- Özdemir Ö. Omalizumab: Pharmacological properties, Primary therapeutic effect mechanisms and adverse effects. *J Otolaryngol Rhinol* 2018;4:42.
- Özdemir Ö, Bozkurt HB, Elmas B. Omalizumab's role in the treatment of steroid dependent malignant idiopathic anaphylaxis. *Turk Pediatri Ars* 2017;52:105-7.
- Pitt TJ, Cisneros N, Kalicinsky C, Becker AB. Successful treatment of idiopathic anaphylaxis in an adolescent. *J Allergy Clin Immunol* 2010;126:415-6.
- Holgate S, Casale T, Wenzel S, Bousquet J, Deniz Y, Reisner C. The antiinflammatory effects of omalizumab confirm the central role of IgE in allergic inflammation. *J Allergy Clin Immunol* 2005;115(3):459-65.
- Lee J. Successful prevention of recurrent anaphylactic events with anti-immunoglobulin E therapy. *Asia Pac Allergy* 2014;4:126-28.
- Demirtürk M, Gelincik A, Colakoğlu B, Dal M, Büyüköztürk S. Promising option in the prevention of idiopathic anaphylaxis omalizumab. *J Dermatol* 2012;39:552-4.