


Acute Ischemic Stroke in the Brainstem After Venom Immunotherapy: A Case Report

Recep EVCEN¹ , Fatih COLKESEN¹ , Eray YILDIZ² , Filiz Sadi AYKAN¹ , Mehmet KILINC¹ , Sevket ARSLAN¹ 

¹ Division of Clinical Immunology and Allergy, Department of Internal Medicine, Necmettin Erbakan University, Meram Faculty of Medicine, Konya, Turkey

² Division of Clinical Immunology and Allergy, Necip Fazıl City Hospital, Kahramanmaraş, Turkey

Corresponding Author: Recep Evcen ✉ r_evcen@hotmail.com

ABSTRACT

Venom immunotherapy (VIT) is one of the most effective treatment methods for allergic diseases. Neurological symptoms are infrequent among systemic reactions. In this case report, the clinical and radiological features of a patient who developed acute brainstem ischemia two hours after a VIT up-dosing phase were evaluated. A 48-year-old male patient developed dyspnea, angioedema, and syncope after a honeybee sting and was diagnosed with anaphylaxis. VIT was started with the conventional schedule (depot extract). The patient went to the emergency department due to numbness in his right arm and impaired speech two hours after VIT was started during an up-dosing phase. In the neurological examination, the patient was conscious and fully cooperative. The pupillary light response, eye movements, and visual field were normal. The right nasolabial groove was faint and consistent with central facial paralysis. Brain diffusion-weight magnetic resonance imaging (MRI) detected diffusion restriction consistent with acute lacunar infarct in the pons. The patient was started on clopidogrel (75 mg/day), atorvastatin (10 mg/day), and levetiracetam (1000 mg/day) treatment. When re-evaluated 30 days later, his muscle strength deficit and speech had improved. VIT is a life-saving treatment option applied in cases of anaphylaxis as a result of bee stings. Although systemic reactions are sometimes observed during the applications, it is rare to see neurological symptoms after VIT. In patients undergoing VIT, one should be vigilant regarding ischemia development, especially during an up-dosing phase.

Keywords: Venom immunotherapy, ischemic stroke, honeybee

INTRODUCTION

Venom immunotherapy (VIT) is one of the most effective treatment methods for allergic diseases. The risk of recurrence of anaphylaxis is 60% in patients who do not receive VIT. In patients receiving VIT, approximately 85-95% do not react when a bee stings again (1). Although VIT is generally well tolerated, treatment-related systemic reactions are observed in 3-12% of patients. Neurological symptoms are infrequent among systemic reactions (2). In this case report, the clinical and radiological features of a patient who developed acute brainstem ischemia two hours after a VIT up-dosing phase were evaluated.

CASE REPORT

A 48-year-old male patient developed dyspnea, angioedema, and syncope after a honeybee sting and was

diagnosed with anaphylaxis. VIT was started with the conventional schedule (depot extract). The patient went to the emergency department due to numbness in his right arm and impaired speech two hours after VIT was started during an up-dosing phase. This unexpected event occurred 14 weeks after the start of treatment and at week 3 of the 4th bottle (40 micrograms/mL). The patient did not have any disease but had a 20 pack-years smoking history.

In the neurological examination, the patient was conscious and fully cooperative. Pupillary light response, eye movements, and visual field were normal. The right nasolabial groove was faint and consistent with central facial paralysis. There was hypoesthesia in the right half of the face. His muscle strength was complete on the left side and 4/5 on the right side. The patient had an ataxic gait and his speech was dysarthric.

Brain diffusion-weight magnetic resonance imaging (MRI) detected diffusion restriction consistent with acute lacunar infarct in the pons (Figure 1). Acute hemorrhage was excluded via brain computer tomography (CT). Based on the present findings, acute ischemic brain stem infarction was considered in the patient. No significant stenosis was observed in the carotids on MR angiography. No thrombus was observed in the heart chambers on transthoracic echocardiography. His left ventricular ejection fraction was 55%. No paroxysmal atrial fibrillation was detected on Holter electrocardiography examination. No abnormality was seen in the tests for the etiology of the thrombosis (Table I).

The patient was started on clopidogrel (75 mg/day), atorvastatin (10 mg/day), and levetiracetam (1000 mg/day) treatment. When re-evaluated 30 days later, his muscle strength deficit and speech had improved. As he had experienced a severe systemic reaction to the honeybee, immunotherapy treatment was continued under antiagregant treatment.

DISCUSSION

VIT is generally a well-tolerated treatment option. Side effects are higher with aqueous extracts, in those sensitive to honeybees, and in patients with a rapid treatment protocol or systemic mastocytosis (2). In most patients, local reactions can be seen during an up-dosing phase. How-

ever, their severity gradually decreases during treatment. Systemic reactions may be more severe, even fatal, and those are more common during an up-dosing phase than with the maintenance phase (3). The symptoms occurred during an up-dosing phase and with honeybee venom in our patient.

Although rare, neurological diseases have been reported with bee stings, including peripheral neuropathies, encephalomyelitis, myasthenia gravis, optic neuritis, par-

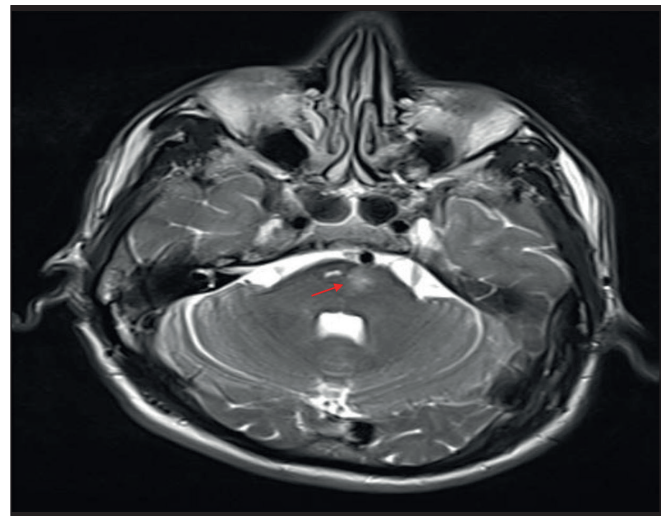


Figure 1. Magnetic resonance image of acute lacunar infarct seen in the pons.

Table I: Laboratory results for the etiology of thrombosis

	Result	Reference		Result	Reference
HGB (g/dL)	14.7	(12.1-17.2)	Protein C (%)	96	(70-140)
PLT (10 ³ /uL)	199	(150-400)	Protein S (%)	96.6	(74-146)
WBC (10 ³ /uL)	6.6	(4-10)	Antithrombin III (%)	97	(83-128)
PT(INR)	0.96	(0.8-1.2)	Homocysteine μ mol/L	13.7	(6-15)
PTT (sec)	28.3	(25-40)	ANTI-ENA Profile	Negative	
Sed rate (mg/h)	8	(0-20)	ANA	Negative	
D-dimer (ng/ml)	135	(0-243)	Anti-cardiolipin IgG	Negative	
Fibrinogen (mg/dl)	334	(200-400)	Anti-cardiolipin IgM	Negative	
Ferritin (ug/L)	96.8	(30-400)	Anti-DS DNA	Negative	
Tsh (mU/L)	3	(0.27-4.2)	Beta-2 microglobulin mg/L	1.69	(0.8-2.2)
C3	1.27	(0.9-1.8)	LDL Cholesterol mg/dl	129	
C4	0.32	(0.1-0.4)	HbA1c %	5.7	(4-6)
Basal tryptase (ug/L)	1.95				

HGB: Hemoglobin, PLT: Platelet, WBC: White blood cell, INR: International normalized ratio, PTT: Partial thromboplastin time, TSH: Thyroid stimulating hormone, ANA: Anti nuclear antibody, HbA1c: Glycosylated hemoglobin

kinsonism, Guillain–Barré syndrome, and cerebral hemorrhage (4,5). In a previous case report, a 60-year-old male presented to the emergency department of the hospital after multiple bee stings. Two hours after the bee sting, sudden onset left-sided hemiplegia and dysarthria developed. In this case, the authors suggested that a systemic immune-mediated reaction to bee sting caused vasoconstriction and a prothrombotic state, resulting in subsequent ischemia and paralysis (6).

In another case, a 45-year-old male presented with right-sided hemiplegia and aphasia due to multiple bee stings. Hyperacute infarction was detected in the left middle cerebral artery region on diffusion MRI (7). However, our patient had acute pons ischemia after immunotherapy prepared from honeybee venom. As a result of detailed ischemia etiology evaluation, no obvious cause was found. The ischemia, which was detected in our patient due to the emergence of symptoms 2 hours after the VIT application, was thought to have developed due to the VIT administration. To our best knowledge, there is no case of stroke developing after immunotherapy as in our case.

The role of bee venom in cerebral ischemia is not fully known. Bee venom contains histamine, thromboxane, leukotrienes, and other vasoactive inflammatory mediators. Both thromboxane and leukotrienes have been shown to cause vasoconstriction, resulting in cerebral infarction (8). Another mechanism is the direct toxic effect of bee venom on the vagus, causing atrial refractoriness to be shortened and arrhythmia (9). Thrombus developing as a result of cardiac arrhythmias can cause cerebral vascular occlusion (10). From the laboratory results requested from the patient, no reason was found to explain the etiology of thrombosis. Arrhythmia was not detected on the ECG Holter, but transient arrhythmia due to VIT could not be excluded. The only detectable risk factor for the patient was his smoking history. The patient's neurological symptoms appeared only two hours after VIT, suggesting that the stroke was induced by immunotherapy.

In conclusion, VIT is a life-saving treatment option applied in cases of anaphylaxis as a result of bee stings. Although systemic reactions may occur in practice, neurological symptoms related to VIT are rare. In patients undergoing VIT, one should be vigilant regarding ischemia development, especially during an up-dosing phase.

Financial Support

None.

Conflict of Interest

There are no conflicts of interest.

Authorship Contributions

Concept: **Recep Evcen, Fatih Çölkesen, Şevket Arslan**, Design: **Eray Yıldız, Mehmet Kılınç, Filiz Sadi Aykan**, Data collection or processing: **Eray Yıldız, Filiz Sadi Aykan, Mehmet Kılınç**, Analysis or Interpretation: **Recep Evcen, Fatih Çölkesen, Şevket Arslan**, Literature search: **Fatih Çölkesen, Filiz Sadi Aykan, Mehmet Kılınç**, Writing: **Recep Evcen, Filiz Sadi Aykan, Mehmet Kılınç**, Approval: **Recep Evcen, Fatih Çölkesen, Şevket Arslan**.

REFERENCES

1. Golden DB, Moffitt J, Nicklas RA, Freeman T, Graft DF, Reisman RE, et al; Joint Task Force on Practice Parameters; American Academy of Allergy, Asthma & Immunology (AAAAI); American College of Allergy, Asthma & Immunology (ACAAI); Joint Council of Allergy, Asthma and Immunology. Stinging insect hypersensitivity: A practice parameter update 2011. *J Allergy Clin Immunol* 2011;127(4):852-4.e1-23.
2. Sin BA, Şahiner ÜM, Akkoç T, Bahçeciler Önder NN, Bingöl G, Büyüköztürk S, et al. Allergen Immunotherapy: National Guideline 2016. *Asthma Allergy Immunology*. 2016;14:84
3. Przybilla B, Ruëff F. Hymenoptera venom allergy. *J Dtsch Dermatol Ges* 2010;8(2):114-27; quiz 128-30.
4. Panagariya A, Sureka RK, Sharma B, Sardana V. Neurological complications following honey bee sting. *J Assoc Physicians India* 1998;46(11):984.
5. Dikici S, Aydin LY, Saritas A, Kudas O, Kandis H. An unusual presentation of bee sting: Subarachnoid hemorrhagia. *Am J Emerg Med* 2012;30(8):1663.e5-6.
6. Temizoz O, Celik Y, Asil T, Balci K, Unlu E, Yilmaz A. Stroke due to bee sting. *Neurologist* 2009;15(1):42-3.
7. Masaraddi SK, Desai RJ, Deshpande SH, Patel S. Bee sting leading to stroke: A case report and review of the literature. *BMJ Case Rep* 2021;14(11):e240693.
8. Schiffman JS, Tang RA, Ulysses E, Dorotheo N, Singh SS, Bahrani HM. Bilateral ischaemic optic neuropathy and stroke after multiple bee stings. *Br J Ophthalmol* 2004;88(12):1596-8.
9. Fisher BA, Antonios TF. Atrial flutter following a wasp sting. *J Postgrad Med* 2003;49(3):254-5.
10. Tisdale JE, Patel RV, Webb CR, Borzak S, Zarowitz BJ. Proarrhythmic effects of intravenous vasopressors. *Ann Pharmacother* 1995;29(3):269-81.