

A case of allergic bronchopulmonary aspergillosis with atypical clinical presentation

Atipik klinikle seyreden bir allerjik bronkopulmoner aspergilloz olgusu*

Sebahat AKOĞLU GENÇ¹, Burçin ÖZER², Cenk BABAYİĞİT¹, Ali BALCI³,
Sinem KARAZİNCİR⁴, Nursel DİKMEN¹

¹ Department of Chest Diseases, Faculty of Medicine, Mustafa Kemal University, Hatay, Turkey
Mustafa Kemal Üniversitesi Tıp Fakültesi, Göğüs Hastalıkları Anabilim Dalı, Hatay, Türkiye

² Department of Medical Microbiology, Faculty of Medicine, Mustafa Kemal University, Hatay, Turkey
Mustafa Kemal Üniversitesi Tıp Fakültesi, Tıbbi Mikrobiyoloji Anabilim Dalı, Hatay, Türkiye

³ Department of Radiology, Faculty of Medicine, Mustafa Kemal University, Hatay, Turkey
Mustafa Kemal Üniversitesi Tıp Fakültesi, Radyoloji Anabilim Dalı, Hatay, Türkiye

⁴ Department of Radiology, Faculty of Medicine, Dokuz Eylül University, Izmir, Turkey
Dokuz Eylül Üniversitesi Tıp Fakültesi, Radyoloji Anabilim Dalı, İzmir, Türkiye

* Bu makale, Toraks Derneği 12. Yıllık Kongresi'nde e-Poster olarak sunulmuştur (e-PS097).

ABSTRACT

Allergic bronchopulmonary aspergillosis (ABPA) is a common hypersensitivity reaction to *Aspergillus fumigatus* in patients with asthma or cystic fibrosis. It is rarely reported in patients without asthma. We hereby presented an ABPA case with an atypical clinical presentation and high attenuation mucoid impaction. Our aim is to emphasize that ABPA can occur with atypical clinical findings.

(*Asthma Allergy Immunol 2012;10:149-152*)

Key words: ABPA, asthma, *Aspergillus fumigatus*

Received: 15/08/2012 • Accepted: 14/09/2012

ÖZ

Allerjik bronkopulmoner aspergilloz (ABPA) astım ya da kistik fibrozisli hastalarda görülen ve *Aspergillus fumigatus*'a karşı gelişen yaygın bir hipersensitivite reaksiyonudur. Astımı olmayan hastalarda da nadiren bildirilmiştir. Burada atipik klinik bulgularla gelen ve "High attenuation mucoid impaction" saptanan bir ABPA olgusu sunulmaktadır. Amaç, ABPA'nın atipik klinik bulgularla ortaya çıkabileceğini vurgulamaktır.

(*Asthma Allergy Immunol 2012;10:149-152*)

Anahtar kelimeler: ABPA, astım, *Aspergillus fumigatus*

Geliş Tarihi: 15/08/2012 • Kabul Ediliş Tarihi: 14/09/2012

Yazışma Adresi/Address for Correspondence

Doç. Dr. Sebahat AKOĞLU GENÇ
Mustafa Kemal Üniversitesi Tıp Fakültesi, Göğüs Hastalıkları Anabilim Dalı, 31120 Antakya-Hatay, Türkiye
e-posta: sebahatakoglu@hotmail.com

INTRODUCTION

Allergic bronchopulmonary aspergillosis (ABPA) is a hypersensitivity reaction usually against *Aspergillus fumigatus* in patients with asthma or cystic fibrosis^[1]. It is reported rarely in patients without asthma^[2]. ABPA appears in 1 to 2% of patients with asthma and 2 to 15% of patients with cystic fibrosis during the course of the disease^[3,4]. A recent meta-analysis demonstrated a prevalence of ABPA in asthma of 12.9%^[5]. If ABPA is unrecognized or poorly treated, airway destruction, bronchiectasis, and/or pulmonary fibrosis result in significant morbidity and mortality^[1]. Because of the indolent nature of the disease, the first step of diagnosis is suspicion^[6]. Radiologic appearance may be misdiagnosed as tuberculosis and malignancy. The aim of this case report is to increase knowledge about ABPA among physicians and emphasize that it can occur with atypical findings.

CASE REPORT

A 31-year-old female presented with chronic cough. She had been diagnosed as smear negative pulmonary tuberculosis eight months ago and treated. Because of lack of response to the treatment, and the suspicious pulmonary mass-like lesion, she had been referred to our clinic. She had no symptoms except for dry cough. She didn't have any atopic history except usage of asthma drug for one month, two years ago. On

physical examination, crackles heard on the left anterior lung field. Chest X-ray showed bilaterally hilar enlargement, nodularity opacity on the left upper zone, and infiltrations on the right upper zone and left paracardiac region. High density mass-like lesion with infiltration on the left upper lobe and paracardiac region, and a tubular density on the right upper lobe were observed on chest computed tomography (CT) (Figure 1). There was no abnormality on bronchoscopic examination except for tenacious mucoid secretions from both bronchial trees. To differentiate lesions from vascular anomaly, CT angiography of the thorax was performed. On CT angiography, characteristics of lesions have changed, atelectasis and bronchiectasis appeared on the left upper lobe, and there was a glove finger appearance on the right upper lobe (Figure 2). These findings with eosinophilia ($2452/\text{mm}^3$) suggested ABPA although there was no asthma diagnosis. Total IgE level was 28.700 IU/mL. Skin prick test and specific IgE for *A. fumigatus* were positive. In sputum culture, *Aspergillus niger* has grown. Pulmonary function tests were performed and showed reversible mild airway obstruction. The patient was diagnosed as ABPA and treatment with prednisolon 40 mg per day and itraconazole 400 mg per day was started. Sweat chloride value was 40 mmol/L. CFTR gene mutation was studied and no mutation was found. After 15 days, cough disappeared, chest X-ray findings mostly reve-

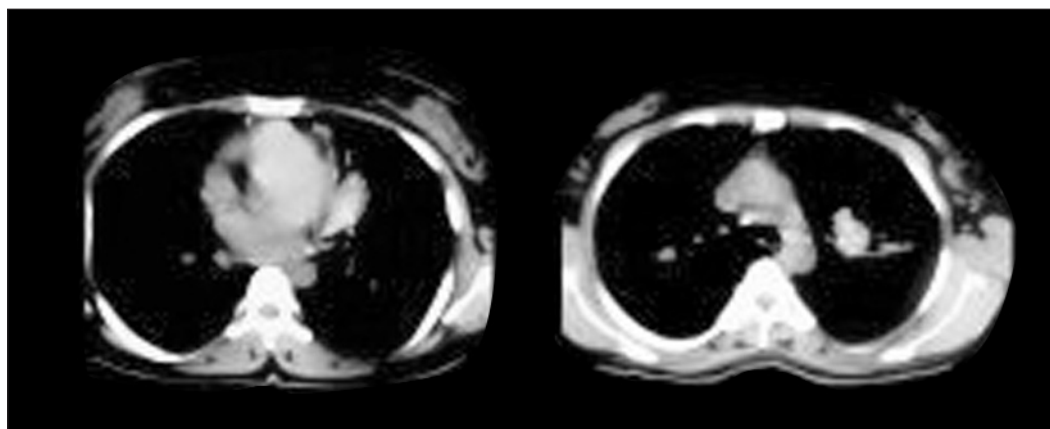


Figure 1. High density mass-like lesion with infiltration on the left upper lobe and paracardiac region, and tubular density on the right upper lobe.

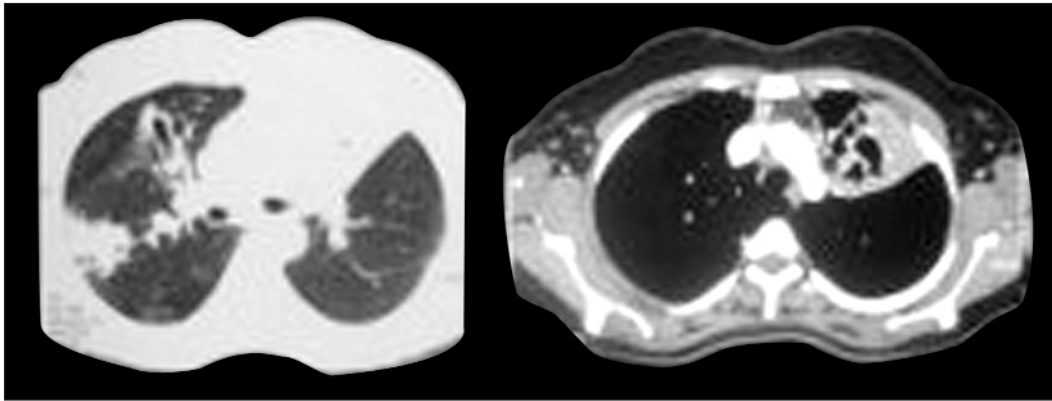


Figure 2. Atelectasis and bronchiectasis on the left upper lobe, and a glove finger appearance on the right upper lobe.

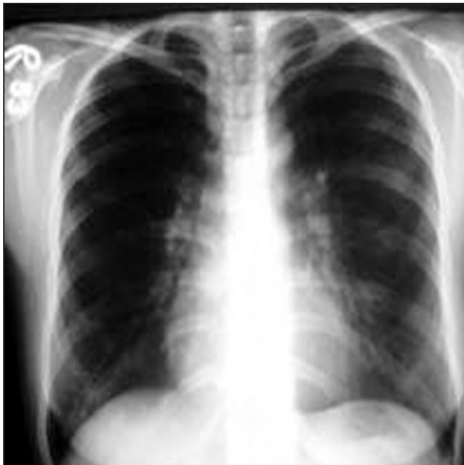

Figure 3. Chest X-ray after treatment.

aled (Figure 3) and total IgE level decreased to 5000 IU/mL. During follow up, IgE level was about 1000 IU/mL. Itraconazole was stopped at second month because of side effects. Steroid doses were gradually tapered, and stopped at sixth month.

DISCUSSION

In asthma patients, ABPA should be kept in mind if the disease is uncontrolled despite appropriate treatment. ABPA can rarely be seen in non-asthmatic patients or both asthma and ABPA can be diagnosed at the same time^[7]. If the patient has no asthma diagnosis, it is likely that these cases are often misdiagnosed initially as bronchogenic carcinoma or pulmonary tuberculosis^[7]. Prasad et al. reported that, 91% of pa-

tients had been misdiagnosed as pulmonary tuberculosis before the diagnosis of ABPA^[8]. Our patient was given asthma medicine two years ago, but on admission, she didn't have asthma symptoms and signs and she was misdiagnosed as tuberculosis.

ABPA cases usually present with recurrent asthma attacks, expectoration of brownish mucus plugs, hemoptysis or systemic symptoms including fever, loss of appetite, and malaise. Our patient had atypical clinical history, because her unique complaint was dry cough. The finding of tenacious mucus plugs on bronchoscopic examination can be seen in ABPA. *A. niger* has grown in sputum culture for fungus. This is accepted as a minor criterion for diagnosis. Because of positive results against *A. fumigatus* in skin prick test and serum specific IgE test, we accepted the cause as *A. fumigatus*.

Pulmonary CT angiography was performed because of the suspected vascular anomaly. The findings of atelectasis and central bronchiectasis and the changing infiltrates with eosinophilia suggested ABPA despite the patient was non-asthmatic.

Eight major criteria were defined for ABPA diagnosis:

1. Asthma,
2. Immediate skin test reactivity to *A. fumigatus*,
3. Elevated serum IgE levels,

4. Transient or fixed pulmonary infiltrates,
5. Central bronchiectasis,
6. Peripheral blood eosinophilia,
7. Elevated specific IgE and/or IgG for *A. fumigatus*,

8. Presence of serum precipitins against *Aspergillus* antigen. However, it is not certain that at least how many criteria are needed for the diagnosis^[3]. Our patient had six criteria. She didn't have typical asthma findings, however there are non-asthmatic ABPA cases in the literature, even rare. Additionally, we couldn't test the precipitins against *Aspergillus* antigen because of inavailability.

A normal serum IgE level excludes ABPA^[7]. Total serum IgE levels are above 1000 ng/mL (420 kU/L) and in acute cases can be above 20.000 ng/mL. The level of total serum IgE was as high as 28.700 IU/mL in our patient. Despite treatment, IgE levels can remain high. In this situation, it should be kept over a lower limit which defined for each patient. Because of it is the most important parameter for the management of the patients, total IgE should be monitored in the first year and then annually^[7]. The total IgE level of our patient did not decrease to normal limit, but drawn a plato over 1000 IU/mL.

ABPA can mimic pulmonary mass rarely^[9]. High-attenuation density within these masses can help narrow the differential diagnosis^[9]. This entity has been rarely described in the literature mainly as case reports^[10,11]. Agarwal et al. reported 18.7% incidence of HAM out of 155 ABPA patients^[12]. Currently, the finding of hyperdense mucus on chest CT is considered a characteristic, but not pathognomonic, finding for ABPA^[13]. In our case, when evaluated retrospectively, the high density tubular lesion on first CT examination was defined as HAM. The term of HAM is used for mucus plugs that is seen more intense than skeletal muscle on chest CT.

In conclusion, ABPA is not always appear with severe asthma or typical clinical signs. Early diagnosis and treatment are of great importance in terms of prevention of complicati-

ons and end stage lung disease. Therefore, in patients without asthma, eosinophilia and changing infiltrations on roentgenogram with HAM on CT should suggest ABPA and total IgE levels should be studied.

REFERENCES

1. Knutsen AP, Slavin RG. Allergic bronchopulmonary aspergillosis in asthma and cystic fibrosis. *Clin Dev Immunol* 2011;2011:843763.
2. Amin MU, Mahmood R. Multiple bronchoceles in a non-asthmatic patient with allergic bronchopulmonary aspergillosis. *J Pak Med Assoc* 2008;58:514-6.
3. Greenberger PA. Clinical aspects of allergic bronchopulmonary aspergillosis. *Front Biosci* 2003;8:119-27.
4. Greenberger PA. Allergic bronchopulmonary aspergillosis. *J Allergy Clin Immunol* 2002;110:685-92.
5. Agarwal R, Aggarwal AN, Gupta D, Jindal SK. *Aspergillus* hypersensitivity and allergic bronchopulmonary aspergillosis in patients with bronchial asthma: a systematic review and meta-analysis. *Int J Tuberc Lung Dis* 2009;13:936-44.
6. Sarkar A, Mukherjee A, Ghoshal AG, Kundu S, Mitra S. Occurrence of allergic bronchopulmonary mycosis in patients with asthma: an Eastern India experience. *Lung India* 2010;27:212-6.
7. Agarwal R. Allergic bronchopulmonary aspergillosis. *Chest* 2009;135:805-26.
8. Prasad R, Sanjay RG, Shukla AD. Allergic bronchopulmonary aspergillosis: a review of 42 patients from a tertiary care center in India. *Lung India* 2009;26:38-40.
9. Agarwal R, Srinivas R, Agarwal AN, Saxena AK. Pulmonary masses in allergic bronchopulmonary aspergillosis: mechanistic explanations. *Respir Care* 2008;53:1744-8.
10. Goyal R, White CS, Templeton PA, Britt EJ, Rubin LJ. High attenuation mucous plugs in allergic bronchopulmonary aspergillosis: CT appearance. *J Comput Assist Tomogr* 1992;16:649-50.
11. Agarwal R, Aggarwal AN, Gupta D. High-attenuation mucus in allergic bronchopulmonary aspergillosis: another cause of diffuse high-attenuation pulmonary abnormality. *AJR Am J Roentgenol* 2006;186:904.
12. Agarwal R, Gupta D, Aggarwal AN, Saxena AK, Chakrabarti A, Jindal SK. Clinical significance of hyperattenuating mucoid impaction in allergic bronchopulmonary aspergillosis: an analysis of 155 patients. *Chest* 2007;132:1183-90.
13. Ritesh Agarwal. High attenuation mucoid impaction in allergic bronchopulmonary aspergillosis. *World J Radiol* 2010;2:41-3.