








# Allergic Contact Dermatitis due to Medical Mask; A Case Report

Gulistan ALPAGAT , Betül DUMANOĞLU , Merve POYRAZ , SumeYra ALAN YALIM , Ayse BACCIOĞLU ,  
Ayse Fusun KALPAKLIOĞLU 

Kırıkkale University, Faculty of Medicine, Division of Allergy and Clinical Immunology, Kırıkkale, Turkey

Corresponding Author: Gulistan ALPAGAT ✉ gulistanalpapat@hotmail.com

## ABSTRACT

Allergic contact dermatitis occurs as a result of delayed hypersensitivity reaction caused by various exogenous substances. Here, a case of allergic contact dermatitis due to medical mask use is presented. A 39-year-old female patient was admitted to Allergy outpatient clinic with complaints of red and itchy maculopapular lesions, and small blisters on the cheeks, nasolabial folds, chin and neck under the chin that started three days ago. She had no chronic illness, massive sunshine exposure, history of systemic and topical medication intake and cosmetic use. The patient has been using washable masks for the whole COVID-19 pandemic period, however she used medical masks instead of washable ones 15 days ago once and for the last two days before the beginning of her complaints. Even though there was no reaction in her first contact, the above dermatitis lesions restricted to mask area developed 24-48 hrs after starting to use it for the second time. Allergic contact dermatitis was diagnosed due to skin lesions suitable with dermatitis and occurrence of the reaction after the second contact to a suspicious substance. She was recommended to stop using medical masks, and a treatment of oral antihistamine and topical steroid was prescribed. After her complaints resolved completely, a challenge with a different brand of medical mask was performed, and no reaction was observed. As a result, this case implicates that allergic contact dermatitis may occur due to using medical masks, and it is important to use masks with standardized approval since they are essential in preventing airborne infections including corona virus.

**Keywords:** Contact dermatitis, COVID-19, medical mask, pandemic

## INTRODUCTION

The clinical picture of coronavirus-19 disease (COVID-19), which was first described in December 2019 in Wuhan, China, with an increasing number of cases worldwide declared as a pandemic by the World Health Organization, varies between asymptomatic to fatal pneumonia. Studies on flu-like diseases and human coronaviruses provide an important evidence that the spread of infectious droplets from infected person to others and the possibility of these droplets contaminating the environment can be prevented by the use of medical masks.

Medical masks are designed to prevent the contamination of diseases and microorganisms from the environment during surgical procedures in operating rooms and

other procedures in the hospitals. It is important to use the mask appropriately that there should be no space between the mask and the face skin and it should cover both the mouth and the nose. There are different mask types such as medical or surgical and washable masks. Even though there may be some undesirable effects, such as itching and difficulty in breathing due to medical masks, to the best of our knowledge there is no report of any diseases due to use of them. Herein, a case of allergic contact dermatitis due to use of medical masks is presented.

## CASE REPORT

A 39-year-old female patient was admitted to Allergy outpatient clinic with complaints of red and itchy maculopapular lesions, and small blisters on the cheeks, nasolabial folds, chin and neck under the chin that

started 3 days ago (Figure 1). She had no chronic illness, massive sunshine exposure, history of systemic and topical medication intake and cosmetic use. The patient has been using washable masks since the beginning of the COVID-19 pandemic, however she used medical masks first 15 days ago for a day and before her symptoms have started for two days. Even though there was no reaction during her first contact, the above dermatitis lesions restricted to mask area developed 24-48 hours after starting to use it for the second time. Allergic contact dermatitis was diagnosed due to skin lesions suitable with dermatitis and occurrence of the reaction after the second contact to a suspicious substance. She was recommended to stop using medical masks, and a treatment of oral antihistamine and topical steroid was prescribed. After her complaints resolved completely, a challenge with a different brand of medical mask with Turkish Standardization Institute (TSI) approval was performed, and no reaction was observed.

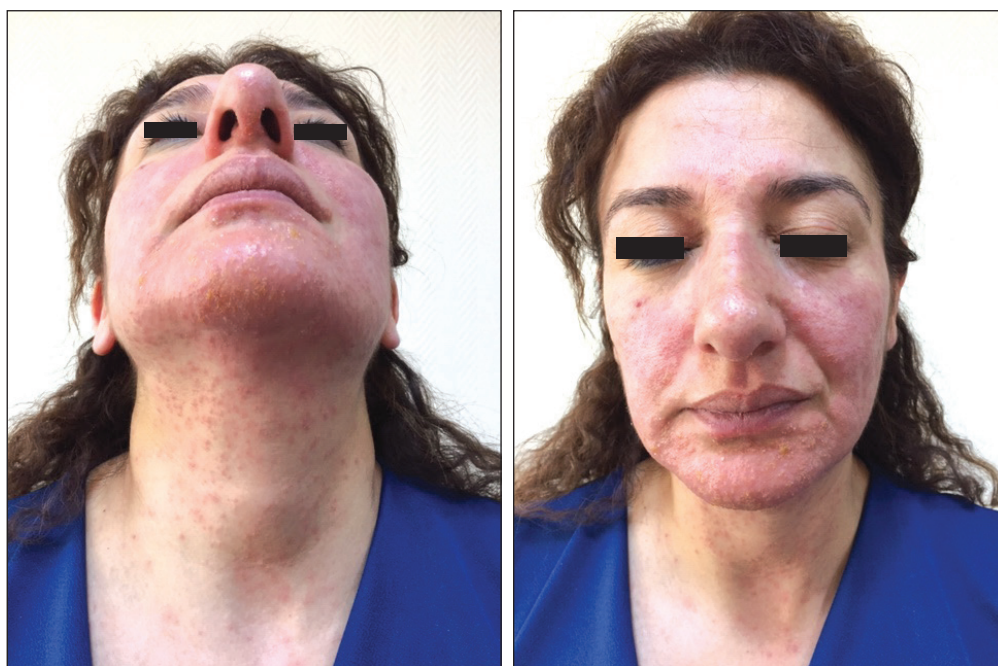## DISCUSSION

Medical masks are used to be worn generally by health-care workers, but nowadays their use is almost essential for everyone in the general population for the prevention of COVID-19 during this pandemic period. The procedure of appropriate mask wearing requires direct contact between the mask and the patient's skin. Its tires should be adjusted to fit all faces and the fabric or paper weight should not

exceed a certain degree depending on the type of the mask. An eczematous skin reaction can occur if a component of the mask is potentially allergenic. Medical masks are produced from 2 or 3-layer paper or special fabrics. They are made of elastane and polypropylene, whereas washable masks are made of polyester and elastane. Medical masks are produced using interlining material and they have metal (steel/ aluminum) wire on the nasal part that allows them to fit properly to the face.

Allergic contact dermatitis (ACD) is an inflammatory dermatosis due to contact of the skin with environmental substances (1). It is a type IV hypersensitivity (2). ACD clinically manifests as pruritic eczematous lesions, erythema, local papules and edema (3-5). The lesions are mostly localized to the site of contact with the allergen; however, systemic reactions can also occur (6,7). When it becomes chronic, erythema and vesicles are seen on a scaly and thick skin (8).

The main diagnostic tool in ACD is the patch test. A systematic review and meta-analysis showed that 20.1% of the general population suffered from contact allergy and the prevalence was twice higher in women compared to men (9). Nickel, cobalt, fragrance allergens, chromium, *p*-phenylenediamine, methylchloroisothiazolinone/methylisothiazolinone, and colophonium are the common allergens (9).



**Figure 1.** Facial contact (skin) dermatitis, with red and itchy maculopapules, and small blisters on the cheeks, nasolabial folds, chin and neck under the chin.

The skin lesions of this case were compatible with acute form of acute dermatitis as erythema, edema, papule, vesicle formations are observed. In subacute form; while vesicles decrease, crusting and desquamation occurrences come to the fore. In the chronic form, the crusty appearance, which becomes evident with thickening of the skin, draws attention (10,11). In differential diagnosis, there is irritant contact dermatitis which is restricted to contact areas. Unlike irritant contact dermatitis, body parts other than the contact area are also involved as in this case such as forehead and neck. A case with facial ACD due to formaldehyde and bronopol in a polypropylene surgical mask mimicked a flare-up of rosacea (12).

Face masks protect people against infection, but they may cause some undesirable effects as in this case. To the best of our knowledge, this is the first report to document the occurrence of an acute allergic reaction to the medical mask used for COVID-19 pandemic prevention. In conclusion, this case implicates that medical masks can cause ACD, and it is important to use masks with standardized approval.

## REFERENCES

1. Lachapelle JM. Historical aspects. In: Frosch PJ, Menné T, Lepoittevin JP, (eds). *Contact Dermatitis*. Berlin, Heidelberg: Springer, 2006:1-7.
2. Rustemeyer T, van Hoogstraten IMW, von Blomberg BME, Scheper RJ. Mechanisms in allergic contact dermatitis. In: Frosch PJ, Menné T, Lepoittevin JP, (eds). *Contact Dermatitis*. Berlin, Heidelberg: Springer, 2006:11-43.
3. Martin SE, Esser PR, Weber FC, Jakob T, Freudenberg MA, Schmidt M, et al. Mechanisms of chemical-induced innate immunity in allergic contact dermatitis. *Allergy Eur J Allergy Clin Immunol* 2011;66:1152-63.
4. Han JH, Lee HJ, Bang CH, Lee JHJY, Park YM, Lee JHJY. P-phenylenediamine hair dye allergy and its clinical characteristics. *Ann Dermatol* 2018;30:316-21.
5. Ahlström MG, Thyssen JP, Wennervaldt M, Menné T, Johansen JD. Nickel allergy and allergic contact dermatitis: A clinical review of immunology, epidemiology, exposure, and treatment. *Contact Dermatitis* 2019;81:227-41.
6. Jacob SE, Barland C, ElSaie ML. Patch-test-induced "flare-up" reactions to neomycin at prior biopsy sites. *Dermatitis* 2008; 19:46-8.
7. Tan CH, Rasool S, Johnston GA. Contact dermatitis: Allergic and irritant. *Clin Dermatol* 2014;32:116-24.
8. Blauvelt A, Hwang ST, Udey MC. Allergic and immunologic diseases of the skin. *J Allergy Clin Immunol* 2003;111:560-70.
9. Alinaghi F, Bennike NH, Egeberg A, Thyssen JP, Johansen JD. Prevalence of contact allergy in the general population: A systematic review and meta-analysis. *Contact Derm* 2019;80:77-85.
10. Mathias CGT. *Occupational Dermatoses in Occupational Medicine*. 3th ed. St Louis: Mosby, 1995:93-131.
11. Drocher LP. *Skin Diseases in Encyclopedia of Occupational Health and Safety*. 4th ed. Geneva: International Labour Office, 1996:12.1-12.19.
12. Aerts O, Dendooven E, Foubert K, Stappers S, Ulicki M, Lambert J. Surgical mask dermatitis caused by formaldehyde (releasers) during the COVID-19 pandemic. *Contact Dermatitis* 2020; 83:172-3.