



# Mortality due to COVID-19 in a Patient with Severe Asthma Receiving Omalizumab Treatment: A Case Report

Mehmet Erdem ÇAKMAK , Saltuk Buğra KAYA , Özge Can BOSTAN , Gülseren TUNCAY ,  
Ebru DAMADOĞLU , Gül KARAKAYA , Ali Fuat KALYONCU 

Department of Chest Diseases, Division of Allergy and Clinical Immunology, Hacettepe University School of Medicine, Ankara, Turkey

Corresponding Author: Mehmet Erdem ÇAKMAK ✉ mehmeterdemcakmak@gmail.com

## ABSTRACT

Coronavirus disease 2019 (COVID-19) originated in Wuhan, China, and caused a pandemic in the world. SARS-CoV-2 infections have a great health risk, especially in patients with chronic diseases. There are concerns that COVID-19 will be more severe in patients with severe asthma. The efficacy and safety of biological agents used in severe asthmatics during SARS-CoV-2 infections are currently unknown. In this case report, we present a patient who had been using omalizumab for five years with the diagnosis of severe asthma and died due to COVID-19. To the best of our knowledge, this is the first case of a Turkish patient who died due to COVID-19 under omalizumab treatment for severe asthma.

**Keywords:** COVID-19, asthma, omalizumab, severe allergic asthma, anti-IgE

## INTRODUCTION

Coronavirus disease 2019 (COVID-19) originated in Wuhan, China and caused a pandemic in the world (1). SARS-CoV-2 infections have a great health risk, especially in patients with chronic diseases (2). GINA (Global Initiative for Asthma) recommends that asthmatic patients continue their controller medications including inhaled corticosteroids, during the COVID-19 outbreak. GINA recommends adding biological agents to the treatment of selected patients with severe asthma to reduce the need for oral corticosteroids (3).

There are concerns that COVID-19 may be more severe, especially in patients with severe asthma who use biological agents. However, the efficacy and safety of treatment with biological agents during SARS-CoV-2 infections are currently unknown. In this case report, we present a severe asthmatic patient who had been using omalizumab for five years and died due to COVID-19.

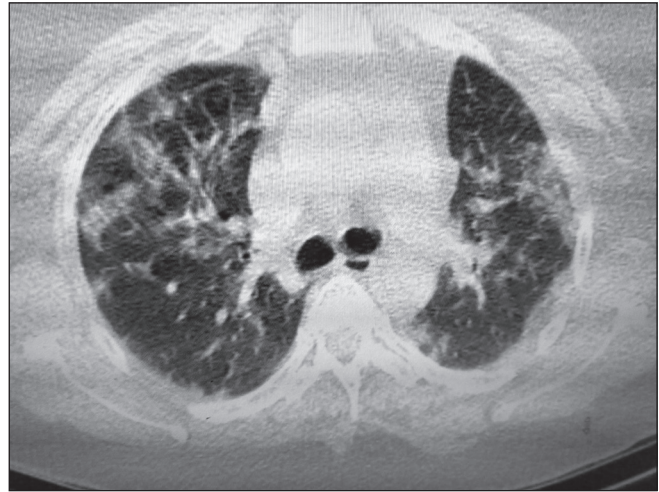
## CASE REPORT

A 54-year-old female patient, who had been followed up at our allergy and immunology clinic with the diagnosis of severe asthma, was referred to our clinic for omalizumab injection. Her medical history revealed that she had FMF (familial Mediterranean fever) for 15 years, diabetes mellitus for two years, asthma for eight years, and obesity (body mass index: 38.9). She had been using salmeterol fluticasone 50/500 mcg 2x1/day, montelukast 10 mg/day, and omalizumab 300 mg/every four weeks with the diagnosis of severe asthma for five years. The patient was referred to the coronavirus outpatient clinic of our hospital due to the complaints of fever, shortness of breath, and cough, at the time of admission for the omalizumab injection. Since the PCR (polymerase chain reaction) test (nasal swab) performed in the coronavirus outpatient clinic was positive, the patient was recommended to use hydroxychloroquine tablet 200 mg 2x1 for five days and isolate herself at home for 14 days. On the second day of hydroxychloroquine treatment, the patient's complaint of

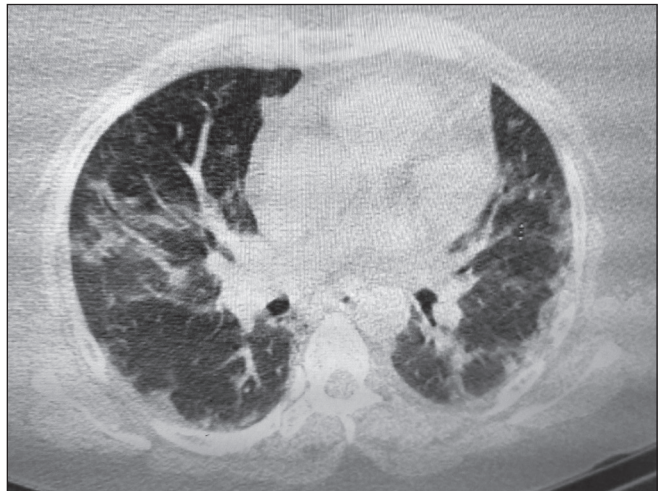
shortness of breath increased and she presented again to the emergency department. On the physical examination performed in the emergency department, fever was 38.2 °C, pulse 108/min, respiratory rate 29/min, blood pressure 90/58 mmHg, and saturation 88% while taking 4 L/min supplemental nasal oxygen. On the respiratory system physical examination, there were rales and rhonchi in both lung fields. Other physical examination findings were normal. The laboratory tests showed: ferritin 86.9 µg/ml (normal: 11-307), C reactive protein (CRP) 20.4 mg/dL (normal: 0-0.5), lactate dehydrogenase (LDH) 251 mg/dL (normal <247), lymphocyte count 900 µL (normal: 1200-3600), sedimentation rate 39 mm/hour (normal: 0-25), procalcitonin 0.023 ng/mL (normal: 0-0.1), troponin-I 2.7 ng/L (normal: 8.4-18.3), and D dimer 0.47 mg/L (normal: 0-0.55). The thoracic computed tomography of the patient revealed opacities and ground-glass densities in the peripheral, lower, and posterior zones in both lungs (Figures 1, 2). Favipiravir was started at a 2x1600 mg first-day loading dose followed by 2x600 mg maintenance dose for five days. Dexamethasone 8 mg/day was added to the treatment and the patient was transferred to the intensive care unit (ICU). As her hypoxemia worsened during ICU follow-ups, she was intubated on the third day of her hospitalization in the intensive care unit and followed up under mechanical ventilation and in the prone position. The patient, who developed septic shock and multi-organ failure during follow-up, died after 14 days in the ICU.

## DISCUSSION

In this case report, we presented a patient who had been using omalizumab for five years with the diagnosis of severe asthma and died due to COVID-19 infection. To the best of our knowledge, this is the first Turkish case receiving omalizumab treatment due to severe asthma who died of COVID-19. It is thought that treatment with omalizumab, an anti-IgE antibody, may protect against severe COVID-19 infection. Omalizumab has been shown to reduce the high-affinity IgE receptors on plasmacytoid dendritic cells and increase the antiviral immune response (4). In the PROSE (Preventative Omalizumab or Step-up Therapy for Severe Fall Exacerbations) study, it was shown that omalizumab caused a decrease in the frequency of viral infections due to decreased expression of high-affinity IgE receptors in plasmacytoid dendritic cells in asthmatic children (5,6). There is limited data in the literature on COVID-19 patients receiving omalizumab. In a study by Domínguez-Ortega J et al., seven of 71 patients with severe asthma who took



**Figure 1.** Radiological imaging of the case; Thoracic computed tomography.



**Figure 2.** Radiological imaging of the case; Thoracic computed tomography.

biological agents were diagnosed with COVID-19. Five of these seven patients were receiving omalizumab treatment. Pneumonia requiring hospitalization was diagnosed in only one of the seven patients receiving omalizumab, and the clinical findings were very mild in the other patients. During the COVID-19 infection, no asthma exacerbation or loss of asthma control was observed in these seven patients (7). In this case we presented, asthma control was impaired during COVID-19 while asthma was under control, and the infection was mortal.

Coronavirus infections other than COVID-19 limited to the upper respiratory tract have been associated with asthma exacerbations (8). The effect of more virulent coronaviruses such as SARS-CoV-2 on asthma control

is not well known. According to the current literature, asthma is not among the top 10 comorbid diseases in patients who die from COVID-19. Comorbid diseases such as diabetes, chronic heart disease, and obesity have been found to be more closely associated with COVID-19-related deaths (9). However, the Center for Disease Control and Prevention (CDC) reported that the most common comorbid diseases in young patients hospitalized with the diagnosis of COVID-19 are obesity, asthma, and diabetes (10). In this case, accompanying comorbid diseases were asthma, diabetes, FMF, and obesity. Concomitant diabetes and obesity may have contributed to the mortality of the case. The impact of asthma on COVID-19 severity remains uncertain. This uncertainty also causes anxiety in healthcare providers and patients.

The anxiety that asthma medications may adversely affect the clinical course of COVID-19 infection causes concern among healthcare providers. Inhaled steroids are the mainstay of asthma treatment and oral steroids are frequently used in asthma exacerbations. *In vitro* studies have shown that corticosteroids inhibit viral cytokines, but not interferons, which are an important antiviral defense mechanism (11). According to the current literature data, it is not possible for us to make a clear judgment about the effects of corticosteroid therapy on the prognosis of COVID-19 in patients with asthma. In addition, there is no data indicating that biological drugs approved for asthma treatment increase the risk of COVID-19. The GINA guidelines also recommend that asthmatic patients continue their current controller medication during the COVID-19 outbreak (3).

In conclusion, the effect of biological agents used in asthma treatment on the clinical course of COVID-19 is unknown. However, biological agents should be preferred over corticosteroids in severe asthma patients requiring regular use of systemic corticosteroids. We think that other comorbid diseases (obesity, diabetes) may have contributed to mortality in this patient with severe asthma who received omalizumab treatment.

## REFERENCES

1. Huang C, Wang Y, Li X, Ren L, Zhao J, Hu Y, et al. Clinical features of patients infected with 2019 novel coronavirus in Wuhan, China. *Lancet* 2020;395(10223):497-506.
2. Docherty AB, Harrison EM, Green CA, Hardwick HE, Pius R, Norman L, et al. Features of 20 133 UK patients in hospital with covid-19 using the ISARIC WHO Clinical Characterisation Protocol: Prospective observational cohort study. *BMJ* 2020;369:m1985.
3. Global Initiative for Asthma (GINA). Global Strategy for Asthma Management and Prevention. Updated 2020. Available from: <https://ginasthma.org/wpcontent/uploads/2020/04/GINA-2020-full-report-final-wms.pdf>. Accessed May 14, 2020.
4. Gill MA, Liu AH, Calatroni A, Krouse RZ, Shao B, Schiltz A, et al. Enhanced plasmacytoid dendritic cell antiviral responses after omalizumab. *J Allergy Clin Immunol* 2018;141(5):1735-43.
5. Teach SJ, Gill MA, Togias A, Sorkness CA, Arbes Jr SJ, Calatroni A, et al. Preseasonal treatment with either omalizumab or an inhaled corticosteroid boost to prevent fall asthma exacerbations. *J Allergy Clin Immunol* 2015;136(6):1476-85.
6. Esquivel A, Busse WW, Calatroni A, Togias AG, Grindle KG, Bochkov YA, et al. Effects of omalizumab on rhinovirus infections, illnesses, and exacerbations of asthma. *Am J Respir Crit Care Med* 2017;196(8):985-92.
7. Domínguez-Ortega J, López-Carrasco V, Barranco P, Ifim M, Luna JA, Romero D, et al. Early experiences of SARS-CoV-2 infection in severe asthmatics receiving biologic therapy. *J Allergy Clin Immunol Pract* 2020;8(8):2784-6.
8. Zheng XY, Xu YJ, Guan WJ, Lin LF. Regional, age and respiratory-secretion-specific prevalence of respiratory viruses associated with asthma exacerbation: A literature review. *Arch Virol* 2018;163(4):845-53.
9. Yin Y, Wunderink RG. MERS, SARS and other coronaviruses as causes of pneumonia. *Respirology* 2018;23(2):130-137.
10. Garg S, Kim L, Whitaker M, O'Halloran A, Cummings C, Holstein R, et al. Hospitalization rates and characteristics of patients hospitalized with laboratory-confirmed coronavirus disease 2019: COVID-NET, 14 states, March 1-30, 2020. *MMWR Morb Mortal Wkly Rep* 2020;69(15):458-64.
11. Oliver BG, Robinson P, Peters M, Black J. Viral infections and asthma: An inflammatory interface? *Eur Respir J* 2014;44(6):1666-81.