



Larynx Angioedema as a Signal in Chronic Lymphocytic Leukemia: A Case-based Guide for Acquired Angioedema in the Setting of Lymphoproliferative Disorders

Zeynep Büşra KISAKÜREK¹ , Sadi Can SÖNMEZ¹ , Emre OSMANBAŞOĞLU² ,
Erman ÖZTÜRK³ , Ayşe Bilge ÖZTÜRK⁴

¹ Koç University School of Medicine, Istanbul, Turkey

² Department of Hematology, Koç University Hospital, Istanbul, Turkey

³ Department of Hematology, Medeniyet University, Goztepe Training and Research Hospital, Istanbul, Turkey

⁴ Department of Pulmonary Medicine, Division of Allergy and Immunology, Koç University School of Medicine, Istanbul, Turkey

Corresponding Author: Ayşe Bilge Öztürk ✉ aysebilgeozturk@yahoo.com

ABSTRACT

Patients with angioedema can present to the internal medicine, emergency medicine, dermatology, or ear nose throat clinics. Physicians may need to assess the patients whose angioedema is unresponsive to antihistamines systematically in collaboration with other subspecialties including hematology, rheumatology, allergy, and immunology. We aimed to provide a concise review of the diagnosis and multi-disciplinary management of acquired angioedema through a case presentation.

A 61-year-old woman presented with recurrent angioedema of 4 episodes within one year. She was evaluated by various disciplines such as dermatology and emergency medicine. Antihistamines and steroids were not effective. The complete blood count (CBC) results indicated lymphocytosis (lymphocyte count=9100 k/ μ L) and further evaluation of the lymphocytosis with flow cytometry immunophenotyping confirmed a diagnosis of chronic lymphocytic leukemia. Since the acquired angioedema diagnosis was confirmed with low C4, C1q, and C1 esterase inhibitor levels, Rituximab 375 mg/m² was administered once a week for 4 weeks. The frequency of attacks decreased after rituximab therapy and none of them were life-threatening.

In conclusion, when the effective treatment is initiated for the primary diagnosis in acquired angioedema, the numerous emergency department visits, hospitalizations, and the mortality due to life-threatening angioedema episodes can be avoided.

Keywords: Angioedema, larynx angioedema, emergency, chronic lymphocytic leukemia, life-threatening angioedema

INTRODUCTION

Angioedema is a potentially life-threatening transient swelling of the subcutaneous or submucosal layers due to mast cell activation or the bradykinin effect (1). The attacks can last 48-72 hours to 5 days with laryngeal edema being the most dangerous form (1). It has both hereditary (mostly young-onset) and acquired forms (adult-onset) (1). Differentiation of the acquired form from the hereditary form, and also the bradykinin-mediated form from those of mast cell origin is important since their management changes accordingly.

It is important to recognize bradykinin-mediated angioedema, which usually does not cause any pruritus or urticaria, when angioedema is unresponsive to antihistamines (1). It is further divided into subgroups, which include hereditary, acquired, and drug-induced angioedema. These are distinguished according to medical history, certain laboratory values (such as C4, C1q protein, and C1 esterase inhibitor) and presentation. Acquired angioedema (with low C4, C1q, and C1 esterase inhibitor) is a rarer condition than hereditary forms (with low C4 and C1 esterase inhibitor but normal C1q), but it holds further significance for the wellbeing of the patient (1,2).

A link between acquired C1 inhibitor deficiency-associated angioedema and other diseases has long been reported (3). Except for the idiopathic group, physicians should be aware of autoimmune diseases (including systemic lupus erythematosus and some other hemolytic diseases of autoimmune origin), lymphoproliferative disorders and malignancies (especially B cell disorders such as Non-Hodgkin Lymphoma), and some infections when they encounter a patient with acquired C1 inhibitor deficiency (3). Although some of these associations need further research, there is substantial evidence about certain theories related especially to autoimmune and cancer processes.

Patients with angioedema can present to internal medicine, emergency medicine, dermatology, and ear nose throat clinics where physicians need to systematically assess these patients who are unresponsive to antihistamines. Collaboration of other subspecialties including hematology, rheumatology, allergy, and immunology should therefore be sought. There must always be a low threshold of suspicion towards, an underlying disorder regardless of which subspecialty the patient presents to. This paper therefore aims to provide a concise review of the diagnosis and multi-disciplinary management of acquired angioedema through a case presentation.

CASE

We report a 61-year-old woman who presented to our allergy outpatient clinic with recurrent angioedema of 4 episodes within one year. Her episodes usually lasted 3 days and manifested as swellings in her extremities, lips, abdomen, and larynx. She was evaluated by various

disciplines such as dermatology and emergency medicine. Antihistamines and steroids were not effective. The patient denied any allergy, history of allergic disease such as asthma or allergic rhinitis, newly started medication, herbal product use, smoking, and similar family history. She did not report any constitutional symptoms including weight loss, fever, chronic pain, fatigue, arthralgia, or night sweats. Her medical history was not significant for long-term medication. Her vital signs were stable on presentation (Table I).

The CBC results indicated lymphocytosis (lymphocyte count=9100 k/ μ L) and the case was referred to hematology. Further evaluation of the lymphocytosis with flow cytometry immunophenotyping confirmed the CLL diagnosis. During the evaluation period, she had another laryngeal edema episode and received i.v. C1-inhibitor concentrate according to the management guidelines (4).

Because of the presence of confirmed acquired angioedema with low C4, C1q, and C1 esterase inhibitor levels, Rituximab 375 mg/ m² was administered once a week for 4 weeks. There was no indication for initiating chemotherapy for her CLL diagnosis. An evaluation was made after Rituximab treatment. Complete remission of CLL was detected and the lymphocyte count had decreased to 1800 k/ μ L. Repeat C1 inhibitor level measurement was performed. The angioedema resolved after the rituximab therapy. However, the C1 inhibitor level and C1 esterase activity remained nearly the same. Two months after cessation of rituximab therapy, the angioedema relapsed. The frequency of the attacks was 2 per year and none of them were life-threatening or involving the larynx.

Table I: Initial work-up of the case.

| Physical Examination | Laboratory Values |
|--|---|
| Respiration: clear on auscultation bilaterally, no wheezes | CBC: lymphocytic leukocytosis Lymphocyte count→9100 k/ μ L HIGH |
| Cardiovascular: Clear S1 and S2, no extra sound | Normal ESR,CRP |
| No organomegaly (splenomegaly, hepatomegaly, lymphadenopathy) or any other sign to indicate an underlying disease process. | Values related to the Complement System and Angioedema Classification: C4→2.4 mg/dL (REF:10-30 mg/dL) LOW C1q→4.5 mg/dL (REF:9-17 mg/dL) LOW C1 esterase inhibitor →3.8 mg/dL (REF:>20-35 mg/dL) LOW C1 esterase activity: 14% (REF: 70-130%) LOW Anti C1-IgG: NEGATIVE ENA Screen: NEGATIVE |
| No physical sign of angioedema was present upon admission. (No swelling, difficulty in respiration.) | No other abnormal primary lab result was found. |

DISCUSSION

B cell proliferation seems to play a key role in the pathogenesis of developing angioedema in a group of patients (5). Such an uncontrolled proliferation of B cells causes or contributes to the development of C1 inhibitor deficiency through some pathways, the main one is generating autoantibodies that bind to the C1 inhibitor, sterically inhibit it, and allow unopposed bradykinin activation, which in turn increases vascular permeability (5). Studies were able to detect these antibodies in a certain group of patients who had concomitant lymphoproliferative disorders such as Non-Hodgkin lymphoma (especially Splenic Marginal Cell Lymphoma) (5). It is worth noting that some of these patients did not have any lymphoproliferative disorder at the time of their emerging angioedema, but they later developed such overt malignancies over time (5). It is therefore important to acknowledge acquired angioedema findings as a possible signaling sign for an underlying disorder.

A substantial portion of patients without any autoantibody led to the proposition of another pathway. Research has shown that there may be an overactivation of the complement system with or without the antibodies leading to the depletion of C1 inhibitor in these patients (6). Exaggerated immune responses are known in patients with certain lymphoproliferative or autoimmune disorders. This overconsumption may be causing angioedema in patients with these diseases as demonstrated by radio-labelling studies, showing increased turnover of C1 inhibitor (6).

This last theory is especially crucial as it also signifies that not only B cell malignancies can cause acquired angioedema findings, but also other malignancies such as chronic lymphocytic leukemia (CLL). CLL is the most common hematologic malignancy in adults. It mostly has an indolent course, and watch and wait treatment is the main follow up modality. Disease progression or symptomatic disease signifies a treatment indication (7). Refractory autoimmune disease with CLL is another chemotherapy

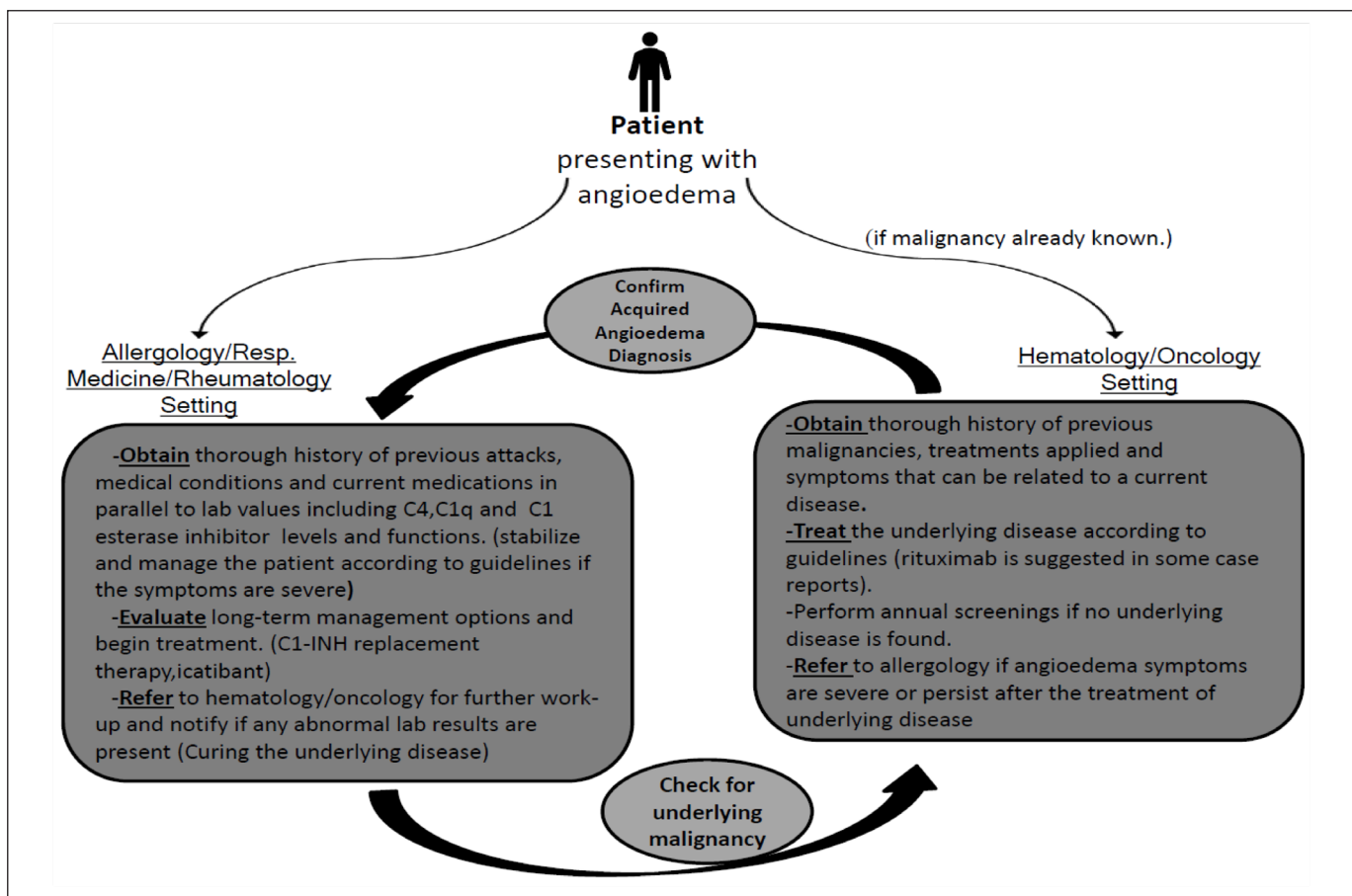


Figure 1. A simple referral scheme for physicians working at various settings for attending a patient with angioedema.

indication. Additionally, CLL is known to cause immune disruption through faulty antigen presentation (7). It mostly causes hematologic manifestations such as hemolytic anemia or thrombocytopenia, but angioedema is also reported (7). In our patient, angioedema was the presenting symptom of the CLL. We could not detect autoantibodies that bind C1 inhibitor in this patient. However, rituximab therapy, which is a chimeric monoclonal antibody that targets CD20 positive B cells and is used to treat certain autoimmune diseases and types of cancer (7), decreased the frequency and severity of angioedema attacks in this patient. While the frequency and severity of angioedema attacks decreased, her C1 inhibitor level and C1 esterase activity remained low. There may be a relation between the C1 esterase level and the angioedema attack frequency. However, the C1 esterase level and activity do not seem to strongly correlate with the number of angioedema attacks. The Food and Drug Administration has approved a C1-INH concentrate and a kallikrein inhibitor called ecallantide for the treatment of acute attacks (4). Long-term treatment involves the treatment of the underlying condition or autoimmune manifestations. A diagram shown in Figure 1 can be used to manage acquired angioedema. We used i.v. C1-inhibitor concentrate for the treatment of angioedema attacks while rituximab therapy decreased the need for C1-INH concentrate.

In conclusion, autoimmune complications are an important feature of CLL, and the patients can present with angioedema only. Regardless of which specialty the patient is referred to, a multidisciplinary work-up is needed to manage symptoms, screen related diseases, and prevent delayed diagnosis in case of acquired

angioedema. When the effective treatment is initiated for the primary diagnosis in acquired angioedema, the numerous emergency department visits, hospitalizations, or mortality due to life-threatening angioedema episodes can be avoided. Cooperation with the allergy department may also help improve care for CLL patients who have angioedema symptoms.

REFERENCES

1. Cicardi M, Zanichelli A. Acquired angioedema. *Allergy Asthma Clin Immunol* 2010;6(1):14.
2. Cicardi M, Aberer W, Banerji A, Bas M, Bernstein JA, Bork K, et al. Classification, diagnosis, and approach to treatment for angioedema: Consensus report from the Hereditary Angioedema International Working Group. *Allergy* 2014;69(5):602-16.
3. Otani IM, Banerji A. Acquired C1 Inhibitor Deficiency. *Immunol Allergy Clin North Am* 2017;37(3):497-511.
4. Castelli R, Zanichelli A, Cicardi M, Cugno M. Acquired C1-inhibitor deficiency and lymphoproliferative disorders: A tight relationship. *Crit Rev Oncol Hematol* 2013;87(3):323-32.
5. Cicardi M, Beretta A, Colombo M, Gioffré D, Cugno M, Agostoni A. Relevance of lymphoproliferative disorders and of anti-C1 inhibitor autoantibodies in acquired angio-oedema. *Clin Exp Immunol* 1996;106(3):475-80.
6. Melamed J, Alper CA, Cicardi M, Rosen FS. The metabolism of C1 inhibitor and C1q in patients with acquired C1-inhibitor deficiency. *J Allergy Clin Immunol* 1986;77(2):322-6.
7. Mohyuddin G, Rabinowitz I. A patient with chronic lymphocytic leukemia and acquired angioedema: Correlation of clinical and biochemical response to CLL therapy. *Ecancermedicalscience* 2013;7:292.